

Diagnostic Accuracy of Fine Needle Aspiration Cytology in a Breast Lump Using Histopathology as Gold Standard

KHALID USMAN, BUSHRA NISAR*, MUHAMMAD SAJID**

ABSTRACT

Aim: To evaluate the diagnostic accuracy of fine needle aspiration cytology in a breast lump using histopathology as gold standard.

Study design: Cross sectional study.

Settings: Department of General Surgery, Bahawal Victoria Hospital, Bahawalpur.

Duration: From 10-03-2011 to 09-09-2011.

Results: Total 200 patients with breast lump were included in this study. Mean age of the patients was 35.45 ± 8.57 . All the patients were divided into different age groups. Ninety (45%) patients were in age group 20-30 years, 47 (23.5%) in age group 31-40 years, 32(16%) were in age group 41-50 years, 29(14.5%) were in age group 51-60 years and 2(1%) patients were in age group >60 years. Gender distribution was done and found 7(3.5%) male patients and 193(96.5%) female patients. Histopathological diagnosis of breast lesions show 53(26.5%) malignant and 147(73.5%) benign cases. Table 3 shows result of FNAC taking histopathology as gold standard. True positive (TP) were recorded as 49(24.5%), 16(8%) false positive (FP), 8(4%) false negative (FN) and 127(63.5%) as true negative (TN), sensitivity was 85.96%, specificity was 88.81%, positive predictive value (PPV) was 75.38% and negative predictive value (NPV) was 94.07%.

Conclusion: The evaluation of diagnostic accuracy of fine needle aspiration cytology in a breast lump using histopathology as gold standard shows a greater sensitivity and specificity, less invasive and cost effective procedure for the diagnosis.

Keywords: Breast lump, diagnostic accuracy, fine needle aspiration cytology

INTRODUCTION

Breast lumps are one of the most prevalent presenting complaints in an outpatient department (OPD) in Pakistan¹. About 90% are benign and of no grave consequences, but malignant lumps contribute to a consequential percentage of all breast lumps. With growing vigilance in the general population, especially about breast pathologies, and the associated solicitude and stress that this condition may lead to, the knowledge that breast cancer can have grim consequences compels patients to seek medical advice^{2,3}.

FNAC is an easily diagnostic method for determining the causes of a breast lesion. Its success is due to its accuracy and cost effectiveness for a breast lump. Therefore, it has many advantages for patients and physicians⁴. This study was conducted to determine the sensitivity and specificity of fine needle aspiration cytology (FNAC), by comparing the results with histopathology.

**Assistant Professor, Department of Histopathology, Sheikh Zayed Medical College/ Hospital, Rahim Yar Khan*
***Medical Officer, Department of Surgery, BVH, Bahawalpur*

Correspondence to: Dr. Khalid Usman, Associate Professor, Email: K_osman37@hotmail.com

METHODOLOGY

Inclusion Criteria: All patients with lump in breast diagnosed clinically with any age and sex were included in the study. Patients with cellulites of breast, breast abscess and breast cysts were excluded from the study.

All patients coming through OPD fulfilling inclusion/exclusion criteria were included in the study. Patients with cellulites, abscesses and cysts were excluded to control confounding variables. The purposes, procedure, risks and benefits of this study were explained and informed consent was taken. After taking the history and examination fine needle aspiration cytology was performed under aseptic conditions by principle investigators having 3 years experience. Smear was sent to laboratory for cytology. Excision biopsy was done for small tumors or lump found benign on fine needle aspiration cytology and histopathology of mastectomy. Specimen will be included as tissue diagnosis. All the relevant information was filled on Performa.

Data was analyzed with the help of SPSS version 10.0 Mean \pm S.D. was presented for age of the patients. Frequencies and percentages were presented for gender distribution. A 2x2 table was used to determine the sensitivity, specificity, accuracy, positive and negative predictive value for

fine needle aspiration cytology taking histopathology as gold standard.

RESULTS

The detail of results is given in tables 1,2,3 & Fig.1 Total 200 patients with breast lump were included in this study. Table 3 shows result of FNAC taking histopathology as gold standard. True positive (TP) were recorded as 49(24.5%), 16(8%) false positive (FP), 8(4%) false negative (FN) and 127(63.5%) as true negative (TN), sensitivity was 85.96%, specificity was 88.81%, positive predictive value (PPV) was 75.38% and negative predictive value (NPV) was 94.07%.

Table 1: Age distribution

Age (years)	n	%age
20-30	90	45
31-40	47	23.5
41-50	32	16
51-60	29	14.5
>60	02	01

Fig. 1: Gender distribution

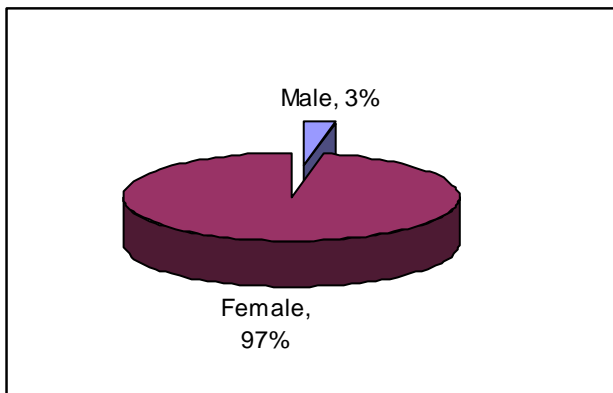


Table 2: Breast lesions on histopathology

Breast Lesion	n	%age
Malignant	53	26.5
Benign	147	73.5

Table 3: Results of FNAC (Histopathology as Gold Standard)

Results of FNAC	Results of histopathology		Total
	Positive (%)	Negative (%)	
Positive	True +ve(a) 49 (24.5%)	False +ve (b) 16(8%)	a + b 65(32.5%)
Negative	False -ve (c) 8(4%)	True -ve (d) 127(63.5%)	c + d 135(67.5%)
Total	A + c 57(28.5%)	b + d 143(71.5%)	n 200

Sensitivity = $a / (a + c) \times 100 = 85.96 \%$
 Specificity = $d / (d + b) \times 100 = 88.81 \%$
 Positive predictive value = $a / (a + b) \times 100 = 75.38 \%$
 Negative predictive value = $d / (d + c) \times 100 = 94.07 \%$

DISCUSSION

Histopathological diagnosis of breast lesions in this study showed 53(26.5%) malignant lesions and 147(73.5%) as benign. Table 3 shows result of FNAC taking histopathology as gold standard. True positive (TP) were recorded as 49(24.5%), 16(8%) false positive (FP), 8(4%) false negative (FN) and 127(63.5%) as true negative (TN), sensitivity was 85.96%, specificity was 88.81%, positive predictive value (PPV) was 75.38% and negative predictive value (NPV) was 94.07%. Different studies have shown false positive results, ranging from 0-2% and false negative ranging from 7-22%^{5,6}. The different reasons given are usually the sampling errors, microscopy errors and the interpretative errors by the cytologists⁷. In different studies the sensitivity and Specificity was 96.3% and 91.4%, in the study of Qureshi et al⁶ it was 80% and 100%, while in other studies it was 96.5% and 96.4%⁸.

In one of the study performed at Khyber Teaching Hospital, Peshawar, Pakistan, from August 2002 to May 2003 the sensitivity and specificity of FNAC was 91.66% and 96.96%, respectively⁹. There are some difficulties and limitations that need to be mention about FNAC, first at all, both false-negative and false-positive results can occur¹⁰. Dysplasia also has a role in the false negative results¹¹. Small size of the tumors and certain histological types (lobular carcinoma, mucinous, tubular or medullary carcinoma) may contribute to false negative results¹². Fine needle aspiration cytology is the simplest method to evaluate breast lesions the results of this procedure are mostly dependent on the size of the lump, experience of the individual performing the procedure and the experience of the cytologist. FNAC has proven to be an effective diagnostic procedure in the evaluation of human breast lesions, and have a high degree of accuracy¹³.

CONCLUSION

The sensitivity and specificity of fine needle aspiration cytology in this study was 85.96% and 88.81%. FNAC is recommended for the diagnosis of breast lumps, however before going for definitive treatment, tissue diagnosis is necessary as there have been cases of false negative results for FNAC.

REFERENCES

1. Aslam S, Hameed S, Afzal T, Hussain A, Zafar H, Naz M et al. Correlation of FNAC and Histological diagnosis in the evaluation of breast lumps. JUMDC. 2012 Jul-Dec; 3(2):1-7.
2. Khemka A, Chakrabarti N, Shah S, Patel V. Palpable Breast Lumps: Fine-Needle Aspiration Cytology versus

- Histopathology: a Correlation of Diagnostic Accuracy. *Internet Journal of Surgery*. 2009;18(1).
3. Qureshi H, Amanullah A, Khan KM, Deebea F. Efficacy of fine needle aspiration cytology in the diagnosis of breast lumps. *JPMI*. 2011;21(4):301-4.
 4. Rupom TU, Choudhury T, Banu SG. Study of Fine Needle Aspiration Cytology of Breast Lump: Correlation of Cytologically Malignant Cases with Their Histological Findings. *BSMMU J*. 2011;4(2):60-64.
 5. Wilkinson EJ, Bland KI. Technique and results of aspiration cytology for diagnosis of benign and malignant diseases of the breast. *Surg Clin North Am* 1990; 70: 801-13.
 6. Qureshi N, Usman N. Comparison of Fine Needle Aspiration Cytology (FNAC) with Histology in palpable breast lump. *Biomedica* 1998; 14: 98-100.
 7. Hatda T, Ishii H, Ichii S, Okada K, Fujiwara Y, Yamamura T. Diagnostic Value of ultrasound guided fine needle aspiration biopsy, core needle biopsy, and evaluation of combined use in the diagnosis of breast lesion. *J Am Coll Surg* 2000; 190: 299-303.
 8. Isaacs RJ, Ford JM, Allan SG, Forgeson GV, Gallagher S. Role of computed tomography in the staging of primary breast cancer. *Br J Surg* 1993; 80:1137.
 9. Khemka A, Chakrabarti N, Shah S, Patel V. Palpable Breast Lumps: Fine-Needle Aspiration Cytology versus Histopathology: a Correlation of Diagnostic Accuracy. *Internet Journal of Surgery*. 2009;18(1).
 10. Bukhari MH, Arshad M, Jamal S, Niazi S, Bashir S, Bakhshi IM. Use of fine-needle aspiration in the evaluation of breast lumps. *Patholog Res Int*. 2011;2011:689521.
 11. Homesh NA, Issa MA, El-Sofiani HA. The diagnostic accuracy of fine needle aspiration cytology versus core needle biopsy for palpable breast lump(s). *Saudi Med J* 2005;26:42-6.
 12. Aziz M, Ahmad N, Zahid J, Faizullah, Aziz M. Comparison of FNAC and open biopsy in palpable breast lumps. *J Coll Physicians Surg Pak* 2004;14: 654-6.
 13. Thompson AM, Dewar JA. Disorders of the breast. In: Cuschieri SA, Steele RJC, Moosa AR. editors. *Essential surgical practice*. 4th ed. London: Arnold, 2002: 61-93.